
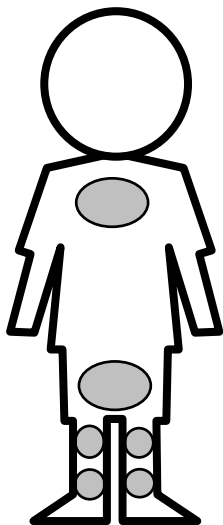


Depiction of Child Abuse Injuries

Location of Typical Abuse-Related Injuries

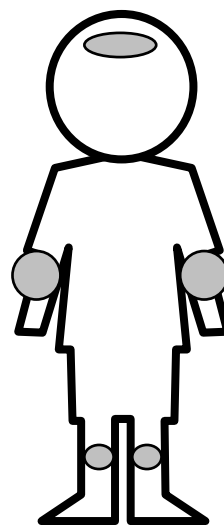


Front View


























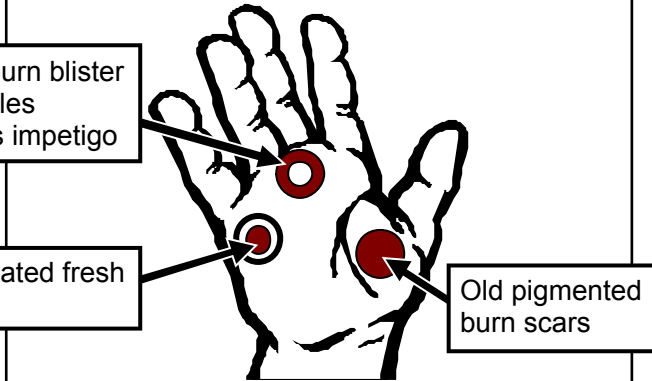



Back View

Location of Typical Accidental Injuries



Front View

| Marks from Instruments | | Burn Marks | |
|---|--|---|---|
| Belt Buckle  | Bite  | Hot Plate  | Fork  |
| Belt  | Sauce Pan  | Light Bulb  | Immersion  |
| Looped Cord  | Paddle  | Curling Iron  | |
| Lash/Whip  | Hair Brush  | Cigarette Lighter  | |
| Fly Swatter  | Spoon  | Steam Iron  | |
| Coat Hanger  | | Knife  | |
| Board  | | Grid  | |
| Hand  | | Cigarette  | |

| Apparently Inflicted Burn Injuries | Apparently Inflicted Restraint Injuries |
|---|---|
| <p>Cigarette burns are usually inflicted on the palms, soles, and buttocks.</p>  <p>Fresh burn blister resembles bulbous impetigo</p> <p>Excavated fresh burn</p> <p>Old pigmented burn scars</p> <p>Burn in various stages of healing indicate repeated abuse</p> | <p>Child may be gagged as punishment or to stop persistent crying.</p> <ul style="list-style-type: none"> Gags leave characteristic bruises at the corners of the mouth.  |
| <p>Abuse must be suspected if burns are in the configuration of common household utensils or appliances. Abuse should also be suspected if the burn is in an area that is typically covered, or in an unusual area, such as the shoulder.</p>  <p>Back View</p> |  <p>Wrists or ankles may be tied as a form of punishment or to keep child "safe".</p> <ul style="list-style-type: none"> Fresh blister may be caused by rope burns. Hyperpigmented, chronic, rope burn injures leave characteristic scars on the wrists and ankles. |